

# Using Digital Infrared Thermal Imaging (DITI) Adjunctively in the Prevention and Treatment of Cancer

Sylvia Philpy, NP, CNS, MSN



**Digital infrared thermal imaging (DITI) is a non-invasive, non-radiation technique which examines thermovascular processes of the body to detect potential pathology. Common clinical uses include early detection of breast cancer risk, monitoring of changes in general health status, monitoring of healing process, and monitoring of treatment efficacy. Imaging can be done on a region of interest, or the whole body can be scanned. Areas of the body that can be assessed include: head and neck (i.e. thyroid, carotids, dental, sinus); breast/chest (i.e. lymph nodes, heart, lungs); abdominal (i.e. liver, gallbladder, esophagus, stomach, spleen, pancreas, GI, colon, bladder, kidneys, pelvis); and full upper body and/or lower body (i.e. neuromuscular/neurovascular).**

Integrated Health Solutions (IHS) is a clinic offering health analysis and support based on a Foundational Wellness model of care. The goal of Foundational Wellness involves a focus of prevention, maintenance, and optimization of mindbody systems and function, regardless of the presence or absence of disease. IHS specializes in adjunctive, integrative cancer care, and health maintenance.

One of the tools that we use in our foundational wellness assessment process is digital infrared thermal imaging (DITI). This is a non-invasive, non-radiation technique, which examines thermovascular processes of the body to detect potential pathology. Common clinical uses include early detection of breast cancer risk, monitoring of changes in general health status, monitoring of healing process, and monitoring of treatment efficacy. Imaging can be done on a region of interest, or the whole body can be scanned. Areas of the body that can be assessed include: head and neck (i.e. thyroid, carotids, dental, sinus); breast/chest (i.e. lymph nodes, heart, lungs); abdominal (i.e. liver, gallbladder, esophagus, stomach, spleen, pancreas, GI, colon, bladder, kidneys, pelvis); and full upper body and/or lower body (i.e. neuromuscular/neurovascular).

### The science behind DITI:

- All objects with a temperature above absolute zero emit infrared radiation from their surface
- Human skin has extremely high emissivity (ability to radiate heat)
- Radiated energy and temperature can be correlated
- Measurements of infrared radiation can

### Thermal Imaging

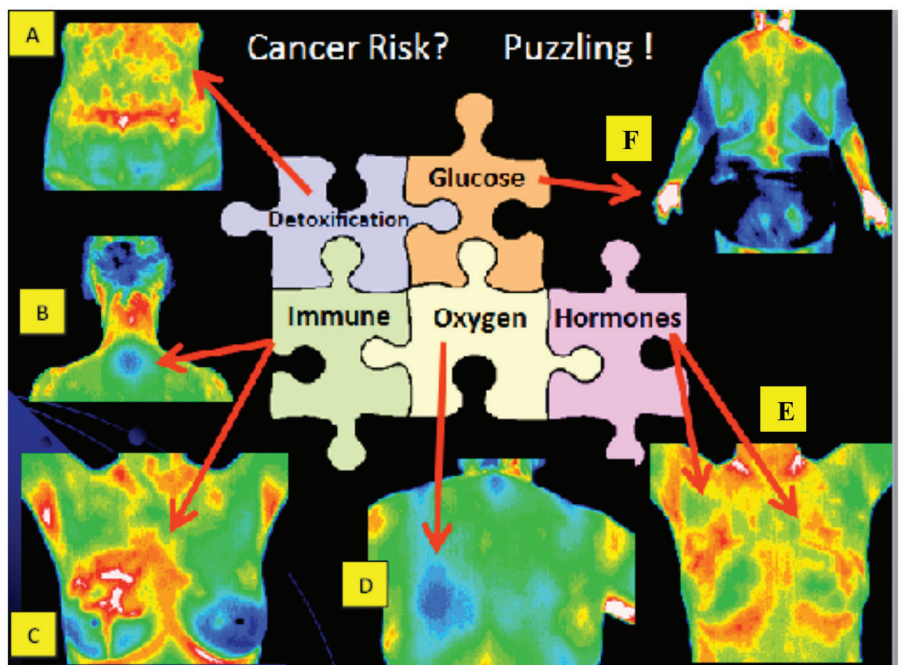
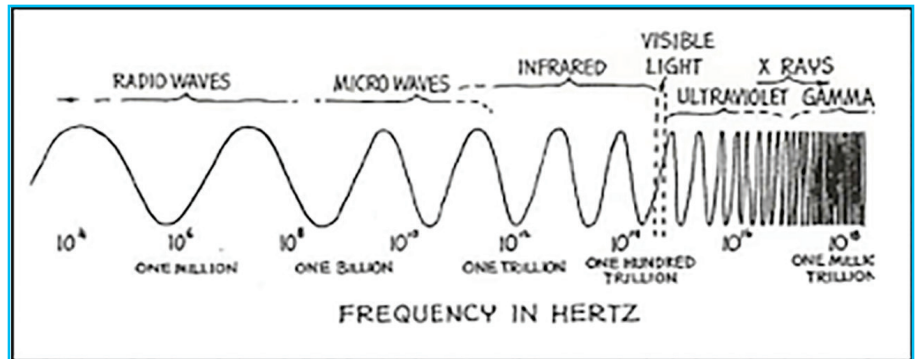


Figure 1: Note the colors above (colors representing degrees of heat) which are radiating off the body and creating an anatomic picture of actual physiologic processes.

be converted directly into accurate temperature values

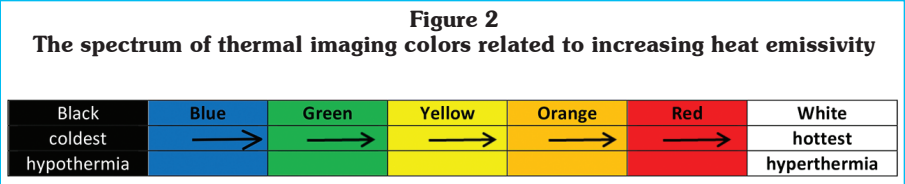
**Thermal Imaging:**

- Detects electromagnetic energy waves in the infrared range (non-visible range)
- Detects thermovascular process
- Detects metabolic process
- Detects inflammatory process
- No body contact
- No radiation
- Useful in women with dense breasts
- Safe for all ages and genders
- Safe for women with implants

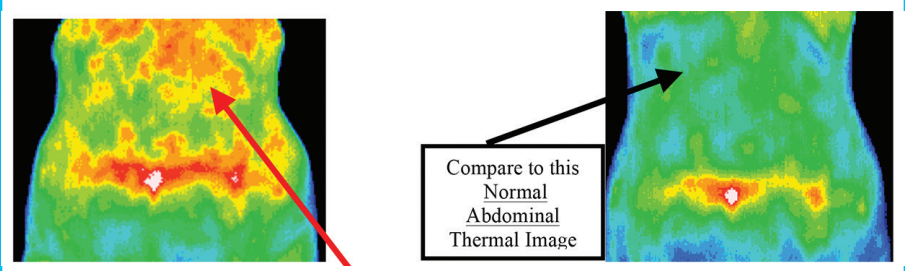
**Thermographic equipment:**

- Early detector range was 2-5 millimicrons
- Heat patterns detected from breast tissue fall into the 8-13 millimicron range
- More accurate current sensors have enhanced the spectral range capability
- Further improved technology use FPA (focal plan arrays) which provide multiple readings of the same spot at the same point in time with digital signal processing correcting for any divergence of information received (digital infrared thermal imaging)
- Industrial FPA technology is not suitable for medical applications because of it's averaging of groups of pixels (medical thermography cameras need to be used for medical application)
- Industrial FPA technology includes temperatures throughout the total range of temperatures seen by the array , which includes the background around the patient, and specificity will be lost
- The more accurate medical thermography camera can measure each pixel as an individual temperature which can be compared to any other pixel to enhance sensitivity and specificity, therefore, the total color range of temperatures (the colormap) are applied to the patient alone (IHS camera capability)
- Older systems operated with a sensitivity of 1.0 degrees centigrade, producing errors ranging from 0.1 to 1.9 degrees
- Pathology found at 0.4-1.0 degrees centigrade
- Current systems are sensitive to 0.01° centigrade (IHS camera capability)

It is important to have an appreciation for the science and the technology that created DITI. The technology itself started as far back as Hippocrates, a Greek physician considered one of the most outstanding men in the history of medicine, and the "father of western medicine." In his writings he described the "mud slurry." The mud slurry was one of the first diagnostic techniques recorded around 480 B.C. The technique involved the spreading of mud

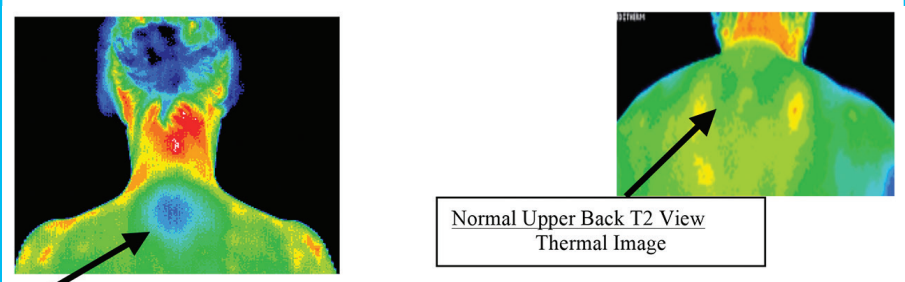


**Figure 3**  
A. Abdominal Thermal Image: how well is the body digesting, eliminating, and detoxifying and how is this related to immune system function and cancer risk?



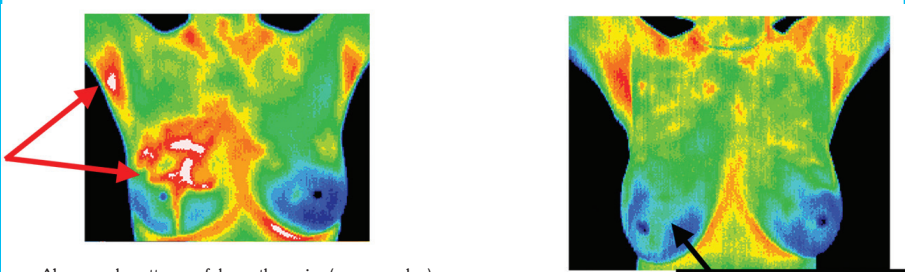
- Diffuse (scattered throughout) hyperthermia (too much heat) in upper abdomen
- Patient having symptoms of gas, bloating, pain in abdomen

B. Posterior View of Upper Back T2 (autoimmune spot): are there any underlying immune dysfunction issues complicating this patient's health care status and cancer risk?



- Hypothermia (too little heat) spot at T2 can be associated with autoimmune disease
- Autoimmune related to thyroid dysfunction, food and environmental sensitivities

C. Anterior Breast View: are there any symptoms, history, other tests and studies that would correlate with this thermal image related to immune system concerns and cancer risk in this patient?



- Abnormal pattern of hypothermia (green color) surrounded by hyperthermia (white & red color)
- Right breast and right axilla hyperthermia (too much heat)
- Right axilla asymmetric hyperthermia compared to left axilla
- Asymmetric (different on each side) breast pattern in right upper breast



over the patient. The area that dried the fastest was thought to be the source of underlying organ pathology. Continued use of this knowledge led to research that became infrared imaging.

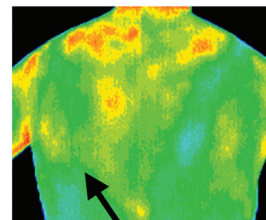
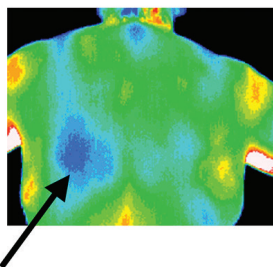
In 1957 Dr. Lawson, a surgeon from McGill University, discovered that “the skin temperature over a cancer of the breast was warmer than normal tissue.” He and another surgeon, Dr. Chughtal, went on to publish an intra-operative study in 1963 demonstrating that the increase in regional skin surface temperature associated with breast cancer was related to venous convection. This research added validity to previous research suggesting that infrared findings were related to both increased vascular flow and increased metabolism. This knowledge has led to the use of DITI in the field of medical oncology. Since tumors usually have an increased blood supply (produce angiogenesis), and since tumors are rapidly dividing (have an increased metabolic rate), thermal imaging can assess temperature gradients compared to surrounding normal tissue and help to identify potential malignancy.

In 1965, Dr. Gershon-Cohen, a radiologist from Albert Einstein Medical Center, introduced infrared imaging to the United States. He studied 4000 patients and showed that infrared thermal imaging had a 94% sensitivity. His work was published in the Cancer Journal for Clinicians in 1968. Since then tremendous evolution of the technology has occurred, research has continued, and many applications have emerged for the use of infrared imaging. One of the most controversial topics studied is the area of breast thermography. Many of the earlier studies were fraught with issues related to uncontrolled variables, such as, type of camera used, the lack of clinical protocols for interpretations (first established in 1980), lack of environmental control decreasing specificity of thermal findings, unfounded premises that thermography could replace mammography rather than be used adjunctively as additional unique information, and untrained technicians performing the scans.

A landmark study increasing interest in using thermography as a tool to assess high risk women for early cancer detection came from Dr. Gautherie in 1983. He published his findings in the American Journal of Obstetrics and Gynecology professing that the group of women he studied with breast cancer using thermography scanning over a 5 year period had a 61% increased survival rate, compared with breast cancer patients that never had thermograms. Of course, the saga continued.

**Figure 3, Continued**

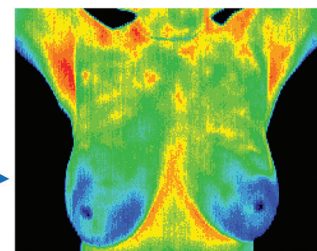
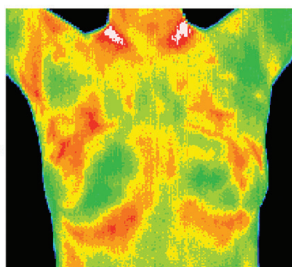
D. Posterior Back View: are there any cardiopulmonary concerns (oxygenation issues) related to this patient’s history, and/or related to cancer risk in this patient?



Normal Back View  
Without Cardiac Risk  
No hypothermia left lower back

- Hypothermia (too cold) pattern in left lower upper back
- Reduction of blood flow to heart causes temperatures to be cold
- Heart concerns evaluated from the left lower back view in female patients

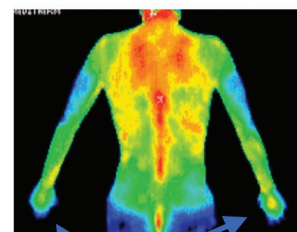
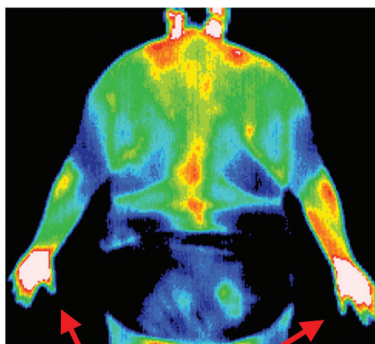
E. Anterior Breast View: Are there any physiologic patterns that correlate with assessing hormone balance in this patient and cancer risk?



Normal Breast  
Thermal Image  
No breast hyperthermia

- Symmetrical (both sides) breast hyperthermia (too much heat)
- History of hormone replacement therapy

F. Posterior Upper Body View: are there any physiologic signs related to metabolic function that can be assessed here that are strongly related to cancer risk?



Normal Hands Posterior Body View  
Thermal Image  
No hyperthermia in hands

- Hyperthermia (too much heat) both hands (“glove pattern”)
- Heat pattern related to insulin resistance and arthritis

**Table 1**  
**Chronology of Noteworthy Clinical Studies**

Date	Source/Author	Results
480 B.C.	Writing of Hippocrates	<ul style="list-style-type: none"> <li>• mud slurry spread over patient</li> <li>• part of body that dried fastest</li> <li>• thought to indicate underlying organ pathology</li> </ul>
1965	Gershon-Cohen; CA-Cancer Journal for Clinicians 18:314-321,1968 <ul style="list-style-type: none"> <li>• Radiologist from Albert Einstein Medical Center</li> <li>• introduced infrared imaging to U.S.</li> </ul>	<ul style="list-style-type: none"> <li>• 4000 patients</li> <li>• Infrared thermal imaging = 94% sensitivity</li> </ul>
1972	•Isard; Roentgenol 115: 811-821, 1972	<ul style="list-style-type: none"> <li>• 10,000 patients over 4 year period</li> <li>• increased mammography detection sensitivity rate 10%</li> </ul>
1972	•G. Dodd; University of Texas Department of Radiology	<ul style="list-style-type: none"> <li>• showed capability of detecting 85% of breast cancers with infrared imaging</li> <li>• suggested elimination of 80-85% of potential mammograms</li> </ul>
1973-1979	<ul style="list-style-type: none"> <li>• BCDDP (Breast Cancer Detection and Demonstration Project)</li> <li>• most frequently quoted reason for decrease use of infrared imaging</li> <li>• large scale, many centers around U.S.</li> </ul>	study problems <ol style="list-style-type: none"> <li>1. untrained technicians performing scans</li> <li>2. radiologists had no experience reading images</li> <li>3. proper laboratory environment controls were ignored</li> <li>4. no standardized reading protocols established</li> <li>5. protocols for interpretation established in 1980</li> </ol>
1980	•Gros, Cancer; 45:51-56	<ul style="list-style-type: none"> <li>• 58,000 women screened</li> <li>• 1,527 with initially healthy breasts and abnormal thermograms followed for 12 years</li> <li>• 40% developed malignancies within 5 years</li> </ul>
1983	Gautherie; Am J Obstet Gynecol (8)147:861-869	<ul style="list-style-type: none"> <li>• 106 patients with breast cancer</li> <li>• initial thermogram abnormal</li> <li>• initial physical exam negative</li> <li>• initial mammogram negative</li> <li>• compared with 372 BRCA patients having no thermograms</li> <li>• patients in both groups subjected to identical treatment, followed for 5 years</li> <li>• thermography group showed 61% increased survival</li> <li>• conclusion that early detection by thermography of high risk women resulted in significant survival benefit</li> </ul>
1986	Nyirjesy, Thermology 1: 170-173	<ul style="list-style-type: none"> <li>• 16,778 participants</li> <li>• compared clinical exam, mammography, &amp; thermography in tumor detection</li> <li>• clinical exam 75% sensitivity</li> <li>• mammography 80% sensitivity</li> <li>• thermography 88% sensitivity</li> <li>• conclusion: best results, multimodal approach</li> </ul>
1998	Keyserlingk, Ahlgren, Yu, Belliveau The Breast Journal 4 (4), 245-251	Sensitivity (true positive) 100 DCIS patients <ul style="list-style-type: none"> <li>• 61% presented w/suspicious palpable abnormality</li> <li>• 85% abnormal mammogram</li> <li>• 83% abnormal thermogram</li> </ul> Specificity (true negative) 100 patients benign disease <ul style="list-style-type: none"> <li>• 84% mammography detection</li> <li>• 81% thermography detection</li> </ul>

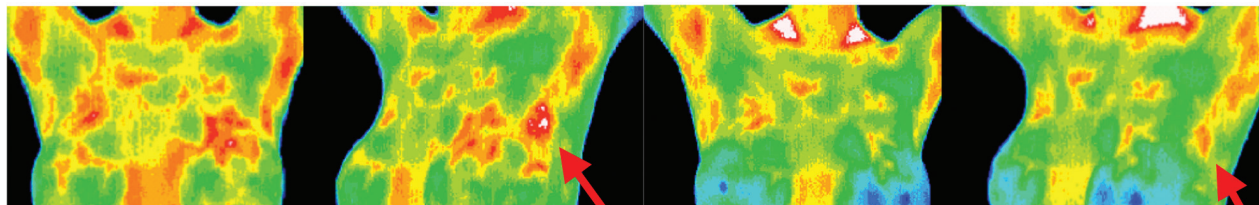


**Table 1 Continued**  
**Chronology of Noteworthy Clinical Studies**

Date	Source/Author	Results
2003	Parisky, Y.R., et. al. American Journal of Radiology (01/03) Efficacy of Computerized Infrared Imaging Analysis to Evaluate Mammographically Suspicious Lesions	<ul style="list-style-type: none"> <li>• 875 biopsied lesions</li> <li>• Thermography 97% sensitivity and a negative predictive value of 95%- 99%</li> </ul> <p>Conclusion: More than 1 million breast biopsies are performed every year in the United States and approximately 75–80% yield a benign outcome. Infrared imaging has a very high negative predictive value, and offers a safe noninvasive procedure that would be valuable as an adjunct to mammography in determining whether a lesion is benign or malignant, thus reducing the need for unnecessary breast biopsies.</p>
2008	Nimmi Arora, MD; et al American Journal of Surgery October 2008 Volume 196, Issue, pg. 523-526 “Effectiveness of a noninvasive digital infrared thermal imaging system in the detection of breast cancer”	<ul style="list-style-type: none"> <li>• 92 patients recommended for biopsy based on mammogram or ultrasound underwent DITI thermal imaging</li> <li>• 60 biopsies malignant; 34 biopsies benign</li> <li>• DITI thermal imaging identified 58/60 malignancies</li> <li>• 97% sensitivity</li> <li>• 44% specificity</li> <li>• 82% negative predictive value</li> <li>• Conclusion: DITI is a valuable adjunct to mammography and ultrasound, especially in women with dense breasts</li> </ul>
2010	G.C. Wishart, M.Campisi, M.Boswell, et.al EJSO European Journal of Surgical Oncology June 2010, Vol. 36, Issue 6 “The Accuracy of Digital Infrared imaging for Breast Cancer Detection in Women Undergoing Breast Biopsy”	<ul style="list-style-type: none"> <li>• 100 women scanned prior to biopsy</li> <li>• 106 biopsies: 65 malignant, 41 benign</li> <li>• DITI 70% sensitivity</li> <li>• DITI 78% specificity</li> <li>• Women &lt;50 combination infrared imaging and mammography = 89% sensitivity</li> </ul>
2011	Clinical Radiology June 2011, Vol. 66, Issue 6 “Digital Infrared Thermal Imaging (DITI) of Breast Lesions: sensitivity and specificity of detection of primary breast cancers”	<ul style="list-style-type: none"> <li>• 126 patients attending one-stop breast clinic <ul style="list-style-type: none"> <li>□ thermography sensitivity = %85%/25% specificity</li> <li>□ ultrasound sensitivity = 88%/91% specificity</li> <li>□ mammography sensitivity = 83%/97% specificity</li> </ul> </li> <li>• Images reported by radiology consultant with extensive experience in breast imaging (but <u>no experience or training in thermography interpretation</u>)</li> <li>• Images reported by a senior surgical research fellow “with experience” in the use and interpretation of the technique (not a trained or certified medical thermologist)</li> <li>• Thermal Rating System (TH scale) used to interpret findings in this study (officially dropped in Thermal Reporting since 2005)</li> <li>• Thermal imaging <u>specificity requires establishing baseline with no change occurring over 3-6 months (not done in this study)</u></li> </ul>
2011	Breast Imaging: A survey Subbhuraam Vinitha Sree, Eddie Yin-KweeNg, Rajendra U Acharya, Oliver Faust World J Clin Oncol, 2011 April 10;2 (4)	<ul style="list-style-type: none"> <li>• Capabilities of different breast imaging techniques currently used is discussed (MRI, ultrasound, mammography, thermography, PET, CT, Optical Imaging, Electrical Impedance Based Imaging)</li> <li>• Thermography is a promising screening tool</li> <li>• <u>Analysis and interpretation of thermogram depends on analysts</u></li> <li>• No single modality is completely useful in all areas of breast cancer management</li> <li>• Improving existing modalities and developing new modalities on the physical, chemical and biological properties of cancerous breast tissue is continually being researched</li> </ul>
2011	FDA News Release June2, 2011	“The FDA has cleared thermography devices for use only as an additional diagnostic tool for breast cancer screening and diagnosis. Therefore, FDA says , thermography devices should not be used as a stand-alone method for breast cancer screening or diagnosis.”

**Collaborative Practice Case Study #1**

- 36 year old Female with fibrocystic breast disease
- FHx (family history) mother with breast cancer
- Drinking 5 cups of coffee/day and smoking

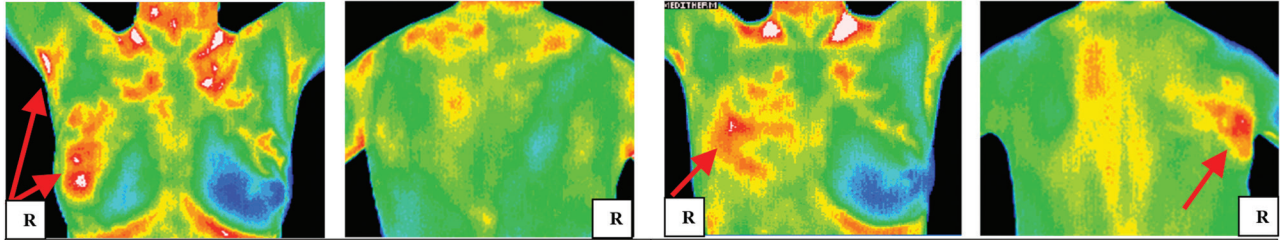


<p><b>Thermography Findings Initial Scan</b></p>	<p><b>Thermography Findings 5 months after initial scan</b></p>
<ul style="list-style-type: none"> <li><input type="checkbox"/> Bilateral hyperthermic patterns in upper breasts</li> <li><input type="checkbox"/> Left &gt; Right</li> <li><input type="checkbox"/> Pattern on LUO breast extends into tail of left breast with focal point of heat (white spot)</li> <li><input type="checkbox"/> Hyperthermic axilla L &gt; R</li> <li><input type="checkbox"/> No neovascularity (new blood vessel formation)</li> <li><input type="checkbox"/> Patterns consistent with fibrocystic breasts</li> <li><input type="checkbox"/> FU thermogram in 3 months (Left breast concern &gt; Right)</li> </ul>	<ul style="list-style-type: none"> <li><input type="checkbox"/> Significant thermal change in 5 months</li> <li><input type="checkbox"/> Breasts overall cooler</li> <li><input type="checkbox"/> Focal point of heat (white spot) in LUO breast no longer evident</li> <li><input type="checkbox"/> Need additional follow-up thermogram in 6 months to determine physiologic stability</li> </ul>
<p><b>Clinical Actions/Outcomes</b></p>	<p><b>Clinical Actions/Outcomes</b></p>
<ul style="list-style-type: none"> <li><input type="checkbox"/> Patient stopped smoking after receiving thermogram results</li> <li><input type="checkbox"/> Patient decreased coffee intake to 1 cup/day</li> <li><input type="checkbox"/> IHS provided clinical suggestions to obtain bilateral breast ultrasound, and lab work to assess hormone balance, adrenal function, and immune system activity</li> <li><input type="checkbox"/> PCP ordered lab and ultrasound</li> <li><input type="checkbox"/> Radiologist determined ultrasound results were negative</li> <li><input type="checkbox"/> PCP started patient on Progesterone cream</li> <li><input type="checkbox"/> IHS started patient on I3C (indole-3-carbinol) as a natural estrogen modulator</li> </ul>	<ul style="list-style-type: none"> <li><input type="checkbox"/> Patient's fibrocystic breast symptoms dissipated</li> <li><input type="checkbox"/> Patient motivated by positive thermogram results to continue lifestyle changes</li> <li><input type="checkbox"/> Patient described feeling much less fear about being at risk for breast cancer because of family history</li> <li><input type="checkbox"/> Patient empowered by making changes that may reduce her cancer risk and could see and feel results</li> <li><input type="checkbox"/> Patient's breast thermogram stable at 6 month follow-up</li> </ul>



## Collaborative Practice Case Study #2

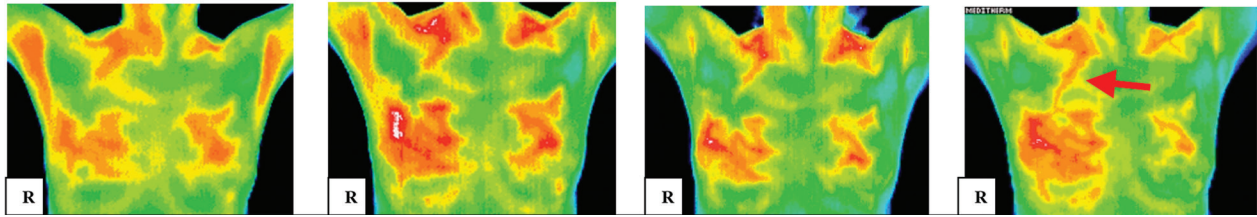
- |   |  |
|---|--|
| <ul style="list-style-type: none"> <li>• 54 year old female</li> <li>• 7 mammograms since age 25</li> <li>• Last mammogram 3 years ago</li> <li>• FU diagnostic mammogram negative</li> </ul> | <ul style="list-style-type: none"> <li>• Hx Fibrocystic Breast Disease</li> <li>• BHRT x 3 years (off x 5 years)</li> <li>• Hypothyroid x 14 years w/Rx</li> <li>• FHx mother w/breast cancer &amp; hypothyroid</li> </ul> |
|---|--|



<p><b>Thermography Findings</b> 08/23/2007 Initial Scan (RU breast and R axilla cancer concern)</p>	<p><b>Thermography Findings Post Mastectomy</b> 2+ year 01/12/2011 3+ years after initial scan RU breast concern for ongoing pathology. Right lung on posterior view metastatic concern</p>
<p><b>Clinical Actions/Outcomes</b></p>	<p><b>Clinical Actions/Outcomes</b></p>
<ul style="list-style-type: none"> <li><input type="checkbox"/> <b>8/23/07 Palpable RUO breast lump, suspicious thermogram, FHx</b></li> <li><input type="checkbox"/> IHS called PCP requested breast US since patient refusing mammogram, PCP faxed order for US same day as thermogram</li> <li><input type="checkbox"/> <b>8/23/07 ultrasound</b> “suspicious for carcinoma”</li> <li><input type="checkbox"/> Patient returned to IHS for consult to discuss risk:benefit of mammogram, which PCP ordered, and to start supplementation</li> <li><input type="checkbox"/> <b>8/28/07 mammogram</b> “highly suspicious lesion RUO breast, with altered architecture and branching suspicious calcifications”</li> <li><input type="checkbox"/> <b>8/30/07 core needle biopsy</b> poorly-differentiated invasive ductal carcinoma, ER+, PR+, Her-2/neu -. PCP referred to oncologist.</li> <li><input type="checkbox"/> <b>9/26/07 PET/CT</b> “extensive nodal metastasis and extensive bone metastasis.” Oncologist plans chemotherapy.</li> <li><input type="checkbox"/> Treatment: <b>Chemotherapy</b> (Taxotere, Cytoxan), surgery, hormone therapy (Femara, and Faslodex)</li> <li><input type="checkbox"/> <b>10/01/08 Recurrent breast cancer</b> resulting in total R breast mastectomy (5 mo. after chemo)</li> <li><input type="checkbox"/> <b>5/2009 Bilateral oophorectomy</b> R ovary breast cancer found 7 months after mastectomy</li> <li><input type="checkbox"/> <b>12/02/10 PET: significant increase in metastatic disease</b> w/multiple foci in liver, multiple osseous lesions @ 17 months</li> </ul>	<ul style="list-style-type: none"> <li><input type="checkbox"/> <b>Patient returns to IHS</b> since oncologist put her in Hospice and she was having difficulty getting out of bed to do basic self care.</li> <li><input type="checkbox"/> <b>FU Thermogram: concerning for chest wall infiltration and lung metastasis</b> (2 + yrs. after mastectomy, 4+ years after metastatic cancer Dx)</li> <li><input type="checkbox"/> IHS worked intensively with patient, and her husband, with integrative oncology adjunctive support (i.e. nutrition, supplementation, medication, IV therapy, and emotional/spiritual support)</li> <li><input type="checkbox"/> Patient started cooking some of her own meals.</li> <li><input type="checkbox"/> Patient started walking daily with her husband again.</li> <li><input type="checkbox"/> Patient drove herself to the beauty shop, which she hadn't been able to do for months.</li> <li><input type="checkbox"/> <b>Quality of life restored while in Hospice.</b></li> </ul>



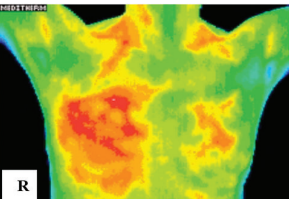
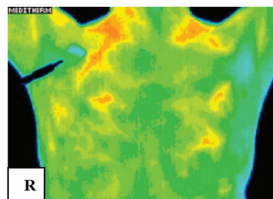
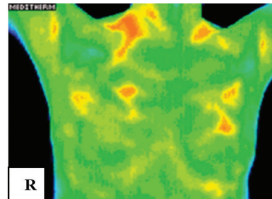
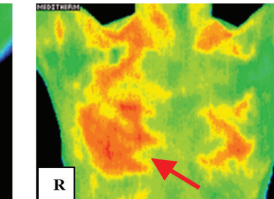
Collaborative Practice Case Study #3



10/28/2004 Thermography Findings Initial Scan	08/02/2007 Thermography Findings 3 years after initial scan	11/12/2007 Thermography Findings FU @3 months since last scan	02/25/2008 Thermography Findings FU @3 months since last scan
<ul style="list-style-type: none"> <li>• Hyperthermic patterns upper breasts R&gt;L</li> <li>• Pattern on R extends into tail of breast</li> <li>• R axilla more hyperthermic</li> <li>• No neovascularity</li> <li>• R breast concern &gt; Left</li> <li>• FU thermogram 3 months</li> </ul>	<ul style="list-style-type: none"> <li>• Palpable R breast mass</li> <li>• Thermal change @ 3 years</li> <li>• Significant increase RUQ</li> <li>• Suspicious of active pathology</li> <li>• Immediate investigation suggested</li> <li>• FU thermogram 3 months</li> </ul>	<ul style="list-style-type: none"> <li>• Thermal change after biopsy</li> <li>• Neovascularity RUO breast</li> <li>• Strongly advise patient seek immediate investigation</li> <li>• FU thermogram 3 months</li> </ul>	<ul style="list-style-type: none"> <li>• Thermal change on scan</li> <li>• Radiating pattern R side</li> <li>• <b>supraclavicular vascular feed</b></li> <li>• Findings may be precursor to <b>aggressive local activity</b></li> <li>• Recommend conventional medical treatment</li> <li>• FU thermogram 3 months</li> </ul>
Clinical Actions/Outcomes	Clinical Actions/Outcomes	Clinical Actions/Outcomes	Clinical Actions/Outcomes
<ul style="list-style-type: none"> <li>• FU thermogram recommended @ 3 months</li> <li>• Lab work, and physical exam recommended to PCP by IHS</li> <li>• Recommendations sent to patient and to PCP</li> <li>• Patient does not follow-up with IHS or PCP x 3 years</li> </ul>	<ul style="list-style-type: none"> <li>• Recommendations to PCP : mammogram, lab, R breast biopsy</li> <li>• PCP orders tests, lab, biopsy</li> <li>• Radiologist finds mammogram calcifications, US = simple cysts</li> <li>• PCP lab normal (CA 27.29 = 7)</li> <li>• Patient initially refuses biopsy</li> <li>• IHS manages diet and lifestyle changes</li> <li>• IHS encourages biopsy</li> <li>• Patient agrees to R breast biopsy (1 month after thermogram)</li> <li>• Invasive R breast cancer ER+ PR+ diagnosed</li> <li>• PCP refers to oncologist</li> </ul>	<ul style="list-style-type: none"> <li>• FU thermogram recommended 3 months</li> <li>• FU w/ PCP recommended</li> <li>• Patient referred to integrative pharmacist for supplement consultation</li> <li>• Patient continues integrative therapies w/IHS (i.e. nutrition, supplementation, lifestyle changes)</li> <li>• Patient continues to refuse to go to oncologist</li> </ul>	<ul style="list-style-type: none"> <li>• Concerning thermogram suggests continued developing pathology</li> <li>• FU thermogram plan 3mos</li> <li>• PCP gets FU cancer marker, result significantly increased in high normal range (CA 27.29 = 28)</li> <li>• PCP refers patient to oncology again</li> <li>• Patient refuses to go to oncologist</li> <li>• Patient continues nutrition, supplementation, diet and lifestyle management</li> </ul>



### Collaborative Case Study #3 Continued

05/05/2008 Thermography Findings FU 10 weeks after last scan	09/24/2008 Thermography Findings FU @ 4 months On chemotherapy x 5 wks	11/17/2008 Thermography Findings FU @ 2 months	03/05/2009 Thermography Findings FU @ 4 months
 <ul style="list-style-type: none"> <li>• Mild thermal change @10 weeks in right breast</li> <li>• Findings may signify clinical improvement</li> <li>• FU thermogram 3 months</li> </ul>	 <ul style="list-style-type: none"> <li>• Resolution of diffuse hyperthermia in breasts</li> <li>• R breast exhibits striking changes consistent with effective treatment</li> <li>• Residual disease cannot be excluded</li> <li>• FU thermogram 3 months</li> </ul>	 <ul style="list-style-type: none"> <li>• No thermal changes in 8 week follow-up</li> <li>• Residual disease cannot be excluded completely</li> <li>• FU thermogram 6 months</li> </ul>	 <ul style="list-style-type: none"> <li>• Thermal change at 4 month follow-up</li> <li>• Thermal activity in central right breast increased</li> <li>• Concerning for active disease</li> <li>• Consider more aggressive treatment</li> </ul>
<p style="text-align: center;">Clinical Actions/Outcomes</p>	<p style="text-align: center;">Clinical Actions/Outcomes</p>	<p style="text-align: center;">Clinical Actions/Outcomes</p>	<p style="text-align: center;">Clinical Actions/Outcomes</p>
<ul style="list-style-type: none"> <li>• No conventional oncology treatment x 9 months since diagnosis</li> <li>• Consistent integrative therapies, (i.e. nutrition, supplementation, diet and lifestyle changes)</li> <li>• Cancer markers have risen but not abnormal, suggesting cancer confinement to breast</li> <li>• Lymph nodes no hyperthermia on thermal imaging or asymmetry, suggesting no axillary involvement</li> <li>• Continued enlargement of cancer mass in R breast. patient discouraged, agrees to oncology consult</li> <li>• Oncologist starts low dose chemotherapy to decrease size of tumor prior to planned excision of mass</li> </ul>	<ul style="list-style-type: none"> <li>• Thermography imaging showing significant positive change after 5 weeks of low dose chemotherapy</li> <li>• Tumor reduced in size</li> <li>• Patient refuses surgery to remove tumor, which oncologist has planned</li> <li>• Patient continues integrative therapies only (i.e. nutrition, supplementation, diet and lifestyle management)</li> <li>• Low dose chemotherapy stopped by oncologist</li> </ul>	<ul style="list-style-type: none"> <li>• Follow-up thermal imaging in 2 months after last scan</li> <li>• Surgical intervention refused again by patient</li> <li>• Patient continues integrative therapies only (i.e. nutrition, supplementation, diet and lifestyle management)</li> <li>• Oncologist unwilling to see patient for continued follow-up</li> </ul>	<ul style="list-style-type: none"> <li>• Follow-up imaging @ 4 months after the last scan</li> <li>• Thermography results concerning for increasing pathology</li> <li>• IHS arranges FU oncology evaluation and goes with patient to oncologist to ensure collaborative care</li> <li>• Oncologist unwilling to restart low dose chemotherapy because trust broken with patient</li> <li>• Patient agrees to surgery without additional chemotherapy</li> <li>• IHS supports and educates patient to ensure she is clear and resolved with her decisions</li> </ul>





2011. The consensus was that analysis and interpretation of thermogram scans depends on the analysts, no single modality is completely useful in all areas of breast cancer management, and improving existing modalities and developing new modalities is continually being researched.

Federal guidelines, however, have been clear regarding the role of thermography imaging since January 28, 1982 when the FDA published its approval and classification of thermography as an adjunctive diagnostic screening procedure for the detection of breast cancer. Then on June 2, 2011 the FDA put out a more current news release restating that “. . . the FDA has cleared thermography devices for use only as an additional diagnostic tool for breast cancer screening and diagnosis. Therefore, FDA says, thermography devices should not be used as a stand-alone method for breast cancer screening or diagnosis.”

At Integrated Health Solutions (IHS), we distinguish ourselves as providers of “Medical Thermography.”

DITI (digital infrared thermal imaging) is done by providers with medical licenses, interpreted only by medical physicians (including diagnostic radiologists), and generate medical reports to medical physicians,

In 2003 Parisky et. al. published a study in the American Journal of Radiology on the “Efficacy of Computerized Infrared Imaging Analysis.” They concluded that thermography showed 97% sensitivity and a negative predictive value of 95-99%. They stated that “infrared imaging . . . offers a safe noninvasive procedure that would be valuable as an adjunct to mammography in determining whether a lesion is benign or malignant, thus reducing the need for unnecessary breast biopsies.”

In 2008 Nimmi Arora et.al published their conclusions in the American Journal of Surgery stating “DITI is a valuable adjunct to mammography and ultrasound, especially in women with dense breasts.” They showed a 97% sensitivity, 44% specificity, and 82% negative predictive value.

In 2010 Wishart et.al., published a paper in the European Journal of Surgical Oncology studying 100 women having DITI scans prior to biopsy. Findings showed 70% sensitivity, and 78% specificity for DITI. When DITI was adjunctively used with mammography the findings improved to 89% sensitivity. These findings echo the sentiment of a comprehensive survey done on breast imaging and published in the World Journal of Clinical Oncology in

which include suggestions for medical management of health concerns. Medical thermography is based on a “best of all worlds approach” to body scanning, and uses thermal imaging adjunctively with standard medical diagnostic techniques. Since “a picture is worth a thousand words” the added value of this tool, and the physiologic information it provides, quickly becomes apparent. Patients are motivated to make important lifestyle changes. Treatment regimens are reinforced, and more readily changed to obtain optimal outcomes for the patient.

Cancer is one of the more complicated, devastating diseases to manage. Using a foundational wellness approach is powerful, because so many cellular pathways predispose to cancer development. There is much written in the literature on the microenvironment that either supports or resists cancer creation. DITI is particularly useful in working with cancer challenges, because the environment can be assessed physiologically. Figure 1 presents these concepts using thermal images. Note the colors (colors representing degrees of heat) which are radiating off the body and creating an anatomic picture of actual physiologic processes. The spectrum of thermal



***Bridging Standard Medical Care  
with Holistic Programs***

**Practitioner and Patient Consultations:  
All Health Concerns**

**Specialty Consultation:**

**DITI/Thermography Clinical Correlation:**

- Any imaging report from any imaging center
- By phone or in-office

**Imaging Services: breast/full body**

**Call 719-573-2254 to Schedule  
[www.integratedhealthsolutions.com](http://www.integratedhealthsolutions.com)**

**Thermography**  
No Radiation

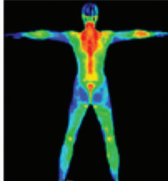
**Breast Cancer Risk**

**Hormone Imbalance**

**Heart/Lung**

**Abdominal**

**Neuromuscular**



<b>Acute &amp; Chronic Health Concerns</b>	<b>Cancer Prevention Support</b>
<p><b>Optimal Health Analysis</b></p> <p><b>Lab Draw &amp; Assessment</b></p> <p><b>Nutritional Therapy</b></p> <p><b>Mindbody Support</b></p>	<p><b>Cancer Prevention</b></p> <p><b>Foundational Health Support</b></p> <p><b>Adjunctive Natural Therapies</b></p> <p><b>Integrative Oncology Support</b></p>



imaging colors related to increasing heat emissivity are shown in Figure 2.

Each of the thermal images connected to the puzzle pieces in Figure 1 represent physiologic information pertinent to assessing cancer risk, and optimizing system function. Individual thermal images shown in Figure 3 are examples of each of those puzzle pieces. A description of each image is included to aide in understanding the pertinent thermal findings, as well as an example of normal findings for comparison (Figure 3).

Standard medical practice utilizes anatomic information, such as PET/CT scans, MRI, mammography, and ultrasound. However, it has been slow to understand the advantages of adding physiologic imaging to the arsenal of cancer risk evaluation. There exists a medical bias that is obstructive to an objective understanding of this less well understood technology. The term “evidence-based” is often used (and at times mis-used) to determine the risk: benefit ratio of utilizing technologies. Below is a chart that chronologically summarizes “evidenced-based” medical literature pertaining to thermal imaging. It is important to note, however, that the “anecdotal” clinical experience and information presented in the above thermal images, as well as in the images seen in the subsequent case studies that will be presented here, have obvious clinical value. In other words, the actual practice of medicine, in its own way, could be considered “evidence based.” Nonetheless, a major randomized controlled trial to determine baseline measurements of sensitivity and specificity would do much to establish clinical efficacy of thermal imaging. However, remember that enough data already exists supporting the clinical use of DITI, that the US FDA has actually approved thermographic imaging as an adjunct to mammography and other diagnostic tools.

A chronology of noteworthy clinical studies are presented in Table 1.

Integrative oncology providers consider cancer a systemic condition. Therefore, body system evaluation is necessary. Metabolic and hormonal disruptions are strongly associated with cancer risk. DITI can be a particularly useful tool because metabolic and hormonal disruptions are generally associated with heat production (i.e. inflammation, increased vascular flow, increasing activity/intensity). In addition, the absence of heat on DITI can be a concerning physiologic finding (i.e. reduced blood flow to the heart, and lungs, or disruption in nerve conduction to T2, associated with autoimmune conditions). Optimal metabolic,

hormonal, cardiopulmonary, and immune function are vital to cancer prevention and treatment strategies.

We have used DITI adjunctively for over 10 years at IHS, and travel throughout western Colorado on a regular basis collaborating with other integrative medical practices utilizing this tool. These practices have come to understand the unique physiologic information DITI provides, and it has created many opportunities for collaboration and cooperation. Thermal imaging is woven into our own integrative medical practice on a regular basis as well.

The IHS collaborative practice model is structured as follows: IHS (Integrated Health Solutions) provides the “thermographer” (certified imaging service); EMI provides electronic medical interpretation (the physician thermologist); IHS then provides clinical correlation services and cooperates with the patient’s PCP (primary care provider); IHS and the PCP cooperate with medical specialists to obtain further tests and studies, determine treatment options, create care plans and follow-up evaluation. This collaborative practice model offers a broad clinical perspective, with more extensive treatment options. Clinical decision making can then be individualized to the patient, their preferences, and the dynamic nature of their particular clinical concerns.

Clinical suggestions made by IHS following DITI physician interpretation have been useful to providers unfamiliar with physiologic testing. Suggestions are dependent on the patient’s history, current diagnosis, clinical symptoms, and medications or treatments they are taking. Suggestions are made based on the extent of thermal findings, the specific location of concerns, the type of pattern and intensity of heat, or absence of heat, and if it is changing over time. Even though initial thermal findings may be significant, it is most important to look for thermal change over time when assessing physiologic findings. A hallmark of a “cancering” condition is that it is always changing over time (growing, spreading, etc.). Thermal imaging is very sensitive,

but thermal change over time improves the specificity of findings. Specificity also requires the addition of other clinical tests/studies, and lab work. Thermal findings focus the clinician on areas of concern that need further assessment and/or treatment which may not be apparent, especially if the patient has no symptoms. Thermal findings also assist in determining existing treatment efficacy, and can support a need for change in treatment plans to better serve the patient. Thermal findings help the clinician to maintain a “systems perspective” because the whole body can be viewed, making functional health concerns more apparent.

Collaborative case studies #1, 2 and 3 are included to provide examples of the process of utilizing DITI in integrative oncology practice.

Cancer risk is truly “puzzling,” and treatment is challenging. It is far better to be too early than too late when determining clinical strategies. Collaborative practice amongst providers ensures the ability of the patient to create a “best of all worlds” approach to obtaining optimal wellness.

Bridge building is the key ingredient in creating collaborative practice. Cooperation starts with the intention and desire to build a team with and for the patient. Bridge building requires a systems approach to care, and a willingness to negotiate, teach, resolve conflict, prioritize, and stay flexible. Bridge burning needs to be averted, fires quenched, and bridges rebuilt when necessary.

An “Integrated Health Solution” requires cooperation and collaboration on many levels. It requires blending skill sets, providing practical knowledge, listening to the patient, keeping an attitude of hope, laughter, and caring. These ingredients create a healing environment that ensures effective outcomes. DITI has been an excellent tool in offering our patients, and our practice, the opportunity to bridge many gaps in the ongoing quest to meet the challenge of cancer.

**Figures and artwork included by permission of the author.**

#### **Sylvia Philpy NP, CNS, MSN**

*Sylvia Philpy, NP, CNS, MSN is currently the clinical director and co-owner of Integrated Health Solutions (IHS) in Colorado Springs, Colorado. Sylvia achieved her master’s degree in nursing, and her clinical nurse specialty training in maternal/child care from the University of Colorado. She received her nurse practitioner training at Georgetown University in Washington DC. Sylvia has been focusing her practice for the past 4 years with special interest in integrative oncology. Sylvia is a Level-3 certified medical thermographer, using DITI for breast cancer screening and fullbody evaluation. Sylvia believes that integrated healthcare is a very personal, co-creative process requiring knowledge, compassion, and caring to obtain optimal foundational wellness. Sylvia believes that foundational wellness is unique to each individual, and dynamic depending on circumstances, intentions, capabilities, and desires.*




# Cancer Strategies Journal: Advances in Integrative Cancer Medicine and Research

[www.cancerstrategiesjournal.com](http://www.cancerstrategiesjournal.com)

**Imagine having a copy of the Cancer Strategies Journal next to you on your desk as an effective guide in your work with cancer.**

## Featured in Each Issue:

- Articles with information about botanicals, nutrition, food and dietary supplements, mistletoe, IV Vitamin C, expanded lab interpretations, research, helpful pharmaceuticals, off-label drugs in cancer medicine, modern cancer medicine (chemotherapeutic, surgical, radiation and diagnostic)
- Cancer treatment and prevention, with new, up to date thinking on cancer care and successful outcomes research, how primary care physicians can become more knowledgeable and participatory with local oncologists and be supportive to their patients therapeutically, and in preventing cancer, social and economic aspects in cancer care
- Ways to educate your patients who are wavering on their choice of care, or who are fearful of not following the one-size-fits-all model of modern medical oncology, insights and tools to help your patients with cancer resolve the hidden conflicts underlying their cancers, giving the body permission to heal, psychological/stress-related issues in cancer care
- Clinical pearls, clinical applications and the thinking behind them, profound outcomes even in serious cases of cancer, and the combination of good science and heartfelt spiritual involvement
- Integrative Medicine Perspectives, Naturopathic Medicine Perspectives, Oriental Medicine Perspectives, Anthroposophical Medicine Perspectives, Ayurvedic Medicine Perspectives, Energy Medicine Perspectives and more



### Subscription Options

**One Year: \$75**

**Two Years: \$130** (You may opt to receive the entire first year and pick up with our current second year, if you choose)

**Reprints: \$7** per reprint plus postage (bulk discounts are available)

**Individual Issues: \$20/issue** plus postage

If international subscription, foreign postage will be added (per issue). Subscription price:

**Canada: \$92.40** per year, includes postage

**Mexico: \$105.40** per year, includes postage

**Overseas: \$113.80** per year, includes postage

## A PEER-REVIEWED JOURNAL

**STAY ON TOP OF THE ONGOING METAMORPHOSIS IN INTEGRATIVE CANCER MEDICINE \*  
PRACTICAL CLINICAL APPROACHES \*  
SIGNIFICANTLY ENHANCE YOUR RESULTS WITH PATIENTS \***

### ORDER FORM - SUBSCRIPTION - CANCER STRATEGIES JOURNAL

Name \_\_\_\_\_ Email \_\_\_\_\_

Mailing Address \_\_\_\_\_ Tel. No. \_\_\_\_\_

City, State, Zip \_\_\_\_\_ **Form of Payment:** Credit Card    Check

Credit Card # (NO AMEX): \_\_\_\_\_ Exp. Date \_\_\_\_\_

3-Digit Code \_\_\_\_\_ Please circle: One Year \$75    Two Years \$130 If international, foreign postage will be added.

Billing address if different from mailing address: \_\_\_\_\_

Please email to [eve@cancerstrategiesjournal.com](mailto:eve@cancerstrategiesjournal.com), fax to (303) 499-0102 or  
mail to 4650 Talbot Drive, Boulder, CO 80303. Make checks payable to Healthy Medicine Academy.

For more subscription options, advertising information, manuscript information, and

**To order online, [www.cancerstrategiesjournal.com](http://www.cancerstrategiesjournal.com).**

*Making Cancer Treatment More Effective with Integrative Oncology*

# Cancer Strategies Journal

## Advances in Integrative Cancer Medicine and Research

Using Digital Infrared Thermal Imaging (DITI) Adjunctively in the Prevention and Treatment of Cancer

Complete Remission of Widely Metastatic Melanoma

Onco-Immunology

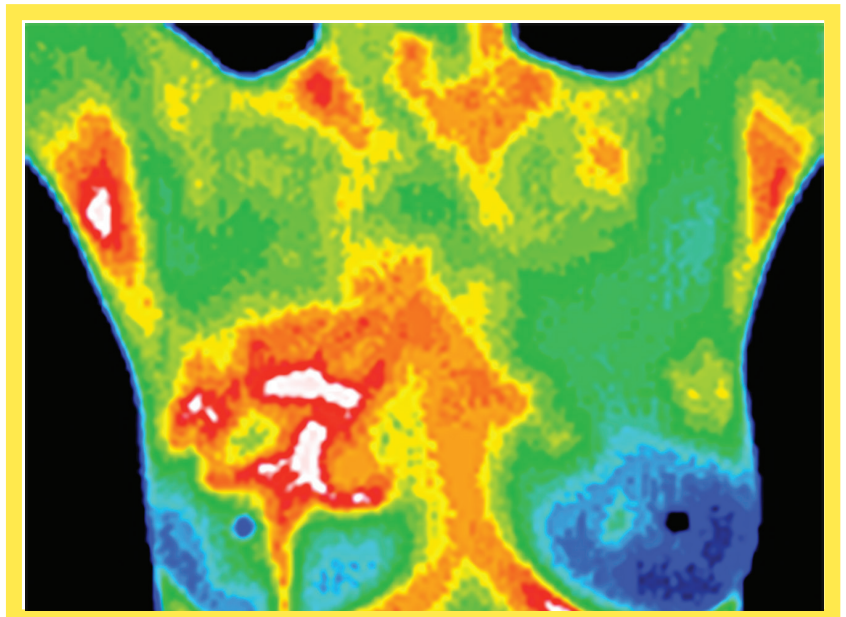
Cancer and Coagulation

Mistletoe Therapy in Cancer Treatment

Clinical Pearls

Addressing the Miasm in Cancer Treatment

Glycemic Restriction in Cancer Patients: A Controlled Interventional Study



A PEER-REVIEWED JOURNAL

**PRACTICAL CLINICAL APPROACHES \***  
**SIGNIFICANTLY ENHANCE YOUR RESULTS WITH PATIENTS \***  
**STAY ON TOP OF THE ONGOING METAMORPHOSIS IN INTEGRATIVE CANCER MEDICINE \***

**Spring 2014**  
**Volume 11, Issue 2**