



Thermography in patients with inflammatory bowel disease and colorectal cancer: evidence and review of the method

MARKO BANIĆ^{1,2}
DARKO KOLARIĆ³
NIKOLA BOROJEVIĆ⁴
ŽELJKO FERENČIĆ⁵
SANJA PLEŠKO⁶
LIDIJA PETRIČUŠIĆ¹
TONČI BOŽIN¹
SVETLANA ANTONINI⁷

¹Division of Gastroenterology, University Hospital Dubrava, Avenija Gojka Suška 6, 10000, Zagreb, Croatia

²School of Medicine, University of Rijeka, Croatia

³Ruđer Bošković Institute, Centre for Informatics and Computing, Zagreb, Croatia

⁴County Hospital Zabok, Department of Radiology, Zabok, Croatia

⁵Children's Hospital Srebrnjak, Department of Pathology, Zagreb, Croatia

⁶Department of Clinical and molecular Microbiology, University Hospital Rebro

⁷MEDNET, Zagreb, Croatia

Correspondence:

Marko Banić
Division of Gastroenterology,
University Hospital Dubrava
Avenija Gojka Suška 6,
10000 Zagreb, Croatia
E-mail: mbanic@kdb.hr

Received December 9, 2012.

Abstract

Background and Purpose: There is a need for a simple, noninvasive and reproducible test that could accurately reflect the inflammatory activity and neoplastic lesions, and that could be used safely and repeatedly during the biological course of inflammatory and neoplastic bowel disease. During past few decades, the joint efforts of professionals have resulted in evolution of technological advances in infrared sensor technology, thus developing the new methods that enabled the use of thermal imaging in biomedical research and clinical medicine. The aim of this viewpoint was to present, and comment on, the possibility of thermal imaging in assessing inflammatory disease activity and the existence of neoplastic bowel lesions.

Materials and Methods: The authors presented thermal images of several patients ($n = 6$: five patients with inflammatory bowel disease and one female patient with colorectal cancer), and one female healthy individual, describing the temperature patterns and commenting on the possible thermographic signs of underlying disease.

Results: Inflammatory bowel disease and colorectal cancer show a clear change in the thermal pattern of the abdominal surface and a different pattern of histogram temperature distribution.

Conclusion: This review has indicated the potential of infrared thermography as a feasible and noninvasive method in additional evaluation of patients with various manifestations of inflammatory bowel disease and also of colon cancer.

INTRODUCTION

Inflammatory bowel disease and colorectal cancer: unmet medical needs

Inflammatory bowel diseases (IBD), Crohn's disease and ulcerative colitis delineate idiopathic chronic inflammation of the small and large intestines. IBD represent relapsing and remitting condition characterized by chronic inflammation at various sites in gastrointestinal tract that result in diarrhea and abdominal pain (1).

Inflammation results as a loss of tolerance to normal intestinal flora, provoking the immune response that includes the release of inflammatory mediators, such as cytokines, interleukins, prostaglandins, nitric

oxide (NO) and tumor necrosis factor (TNF), (2-3). The etiopathogenetic factors of the loss of tolerance to normal host microbiota and subsequent chronic inflammatory cascade include multifactorial genetic predisposition that can lead to abnormal epithelial barrier and altered mucosal immune defense (4-6).

Diagnostic evaluation of inflammatory bowel diseases includes clinical examination, laboratory tests, activity indices and imaging methods, such as endoscopy and radiology methods. However, there is a need for a simple, noninvasive and reproducible test that could accurately reflect the disease activity, and that could be used safely and repeatedly during the biological course of inflammatory bowel disease.

Colorectal cancer is the third most common tumor in the United States. The disease is uncommon before the age of 40, but rises sharply after the age of 55. Several risk factors have been identified including a diet high in fat content, lack of dietary fiber, alcohol consumption, some types of occupational exposures (including solvents and fuel oils), a history of inflammatory bowel disease (such as Crohn's disease or ulcerative colitis), prior radiation treatments and the presence of a first degree relative with the disease.

Over the past decade, much has been learned about the biology and genetics of colorectal cancer. It is now well established that in most cases these tumors arise from polyps. For tumors localized only within the mucosa or within the colonic wall (stage I), 5-year survival rates of 85–95% have been recorded. For tumors penetrating through the colon wall (stage II), 5-year survival rates are 30–70%. Tumors that involve lymph nodes (stage III) or have spread to distant sites (stage IV) have poorer prognosis. This has led to intensive efforts to reduce colorectal cancers by detecting and treating polyps and / or precancerous lesions at early stage, with implementation of intensive screening programs that have also started in European countries, including Croatia. These programs have been limited by increased costs of methods that have been planned for screening and rather low compliance of the population at risk. There is also the question of the incidence of interval cancers due to the quality of endoscopy procedures (7). Consequently, there is a need for additional noninvasive method that could possibly complement standard methods in detection of colon cancer at early stage.

The use of thermography in biomedical research and clinical practice

The use of thermography in clinical practice is an idea that has been persisting for almost forty years, since the first attempts to measure and map skin temperatures were made in 1960s (8). However, due to technological and technical limitations of the method in those times, thermography did not get into wider use in clinical practice. The drive of biomedical industry with consequent rapid development in other areas of biomedical imaging has also strongly influenced the destiny of thermography

in biomedical practice. During past few decades, the joint efforts of biomedical engineering and medical professionals have resulted in evolution of technological advances in infrared sensor technology, image processing, knowledge-based databases, and their overall integration into a system. All these enabled the new methods of research and use in medical infrared imaging (9). Today, thermography has found its application in clinical medicine, such as in breast and skin oncology, vascular disorders, arthritis and rheumatism, sports and rehabilitation medicine, and infrared imaging that includes static (classical) method, dynamic method, multispectral imaging and thermal texture mapping (thermal tomography) (9). Up to now, there has been no sufficient data in regard to thermographic analysis of inflammatory bowel diseases and colorectal cancer.

The aim of this viewpoint was to present the possibility of thermal imaging in various manifestations of inflammatory bowel disease and colorectal cancer.

PATIENTS AND METHODS

For the purpose of this study, the patients with various manifestations of inflammatory bowel disease ($n = 5$) and colorectal cancer ($n = 1$) underwent the standard diagnostic work-up that included physical exam, laboratory tests, including C-reactive protein, esophagogastroduodenoscopy and total colonoscopy with terminal ileoscopy, as well. The microbiology testing of stool samples, including A / B *Cl. difficile* toxin was performed in order to detect a potential intestinal pathogen. The magnetic resonance (MR) imaging of the abdomen and / or MR enterocolography were done in order to exclude the diagnosis of bowel disorders other than inflammatory bowel disease and colon cancer. In addition, a healthy female person ($n = 1$) without clinical and laboratory signs (including ultrasonography examination) of abdominal disease was also included in the analysis. All the persons included into the study ($n = 7$) underwent thermal imaging. The method of thermography used was a classical one with the static manner of imaging. Thermal imaging was performed in real time using infrared camera Thermo Tracer TH7102102WL (NEC Sanei Instruments, Ltd., Japan) and ThermoMED proprietary software developed at the Ruđer Bošković Institute (Zagreb, Croatia), during all measurements (10-12). Air temperature and humidity of the imaging room were stable, with maximum temperature oscillation of ± 1 °C. All thermographic images were made in the same room at approximately the same time of the day. The measurements were done before preparations for endoscopy to exclude the potential influence of bowel cleansing and endoscopic procedure itself (13). The abnormalities observed by thermal imaging were based on associated thermal asymmetry between normal and abnormal sites (peak surface temperature), a change in normal temperature gradients (Δ temperature) and disturbance of the normal physiological temperature distribution pattern (histograms of pixels under the observed temperature).

THERMOGRAPHY IN INFLAMMATORY BOWEL DISEASE AND COLORECTAL CANCER: EVIDENCE OF THE CONCEPT

The principle of thermography is based on the observation that all objects emit infrared radiation (wavelength ranging 7–15 μm) at differing level, depending on their temperature. In classical, static thermal imaging, the thermal image obtained by infrared camera represents a two-dimensional distribution of the emitted infrared radiation, reflecting the object’s temperature, observed at a point of time (14). The physiologic basis of thermography relies on capacity and ability of various biologically active substances (histamine, prostaglandins, nitric oxide) to block normal neural control of blood flow in the skin, thus reflecting increased »metabolic heat« of deeper tissues and organs (15).

1. Active colonic inflammation

Figure 1 presents the abdominal thermal image of a healthy female individual and a normal temperature histogram with a peak temperature around 32°C and a normal distribution pattern.

Figure 2 shows the thermal image of female patients with active Crohn’s colitis

where a clear change in the thermal pattern of the abdominal surface is observed, and a histogram of a patient with Crohn’s colitis with peak temperature around 35°C, showing a different pattern of histogram temperature distribution.

2. Surveillance of active pancolitis and evaluation of therapeutic effect

Figure 3 is showing a thermal image of a female patient with active ulcerative pancolitis. Peak temperature before therapy was around 32.5°C.

Figure 4 demonstrates a thermal image after induction of remission following active pancolitis where a

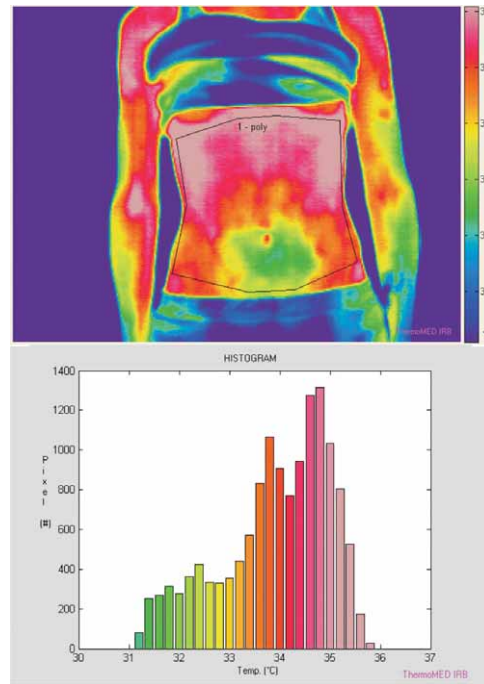


Figure 2 (a and b). Thermal image of female patients with active Crohn’s colitis.

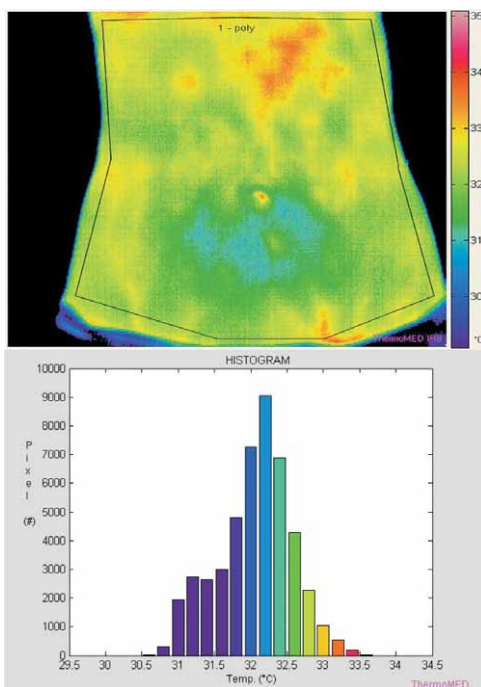


Figure 1 (a and b). Abdominal thermal image of a healthy female individual and a normal temperature histogram.

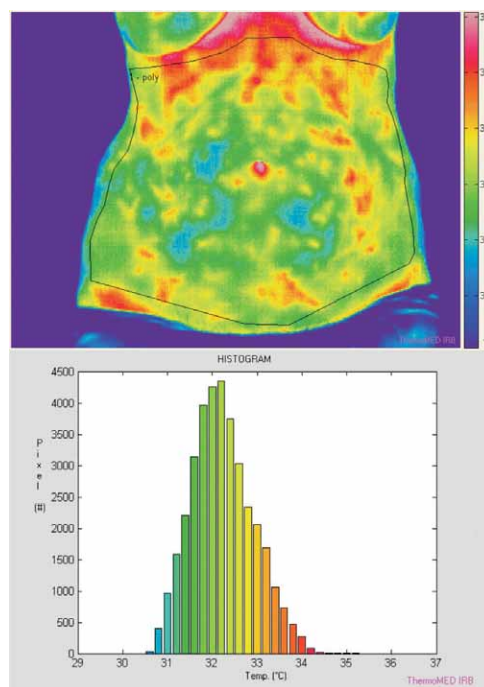


Figure 3 (a and b). Thermal image of a female patient with active ulcerative pancolitis

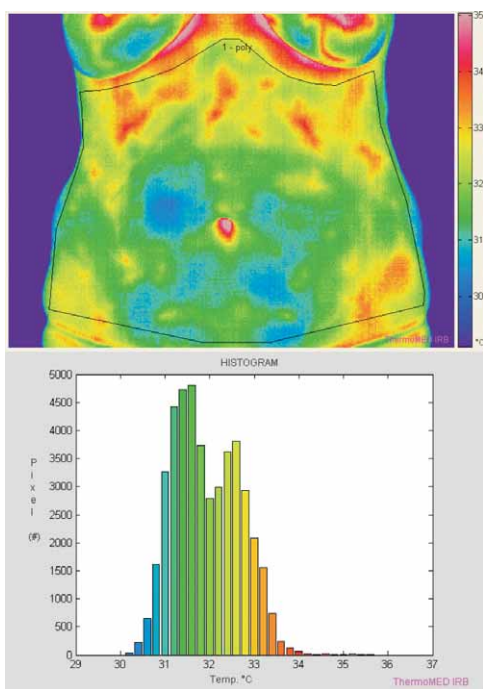


Figure 4 (a and b). Thermal image after induction of remission following active pancolitis.

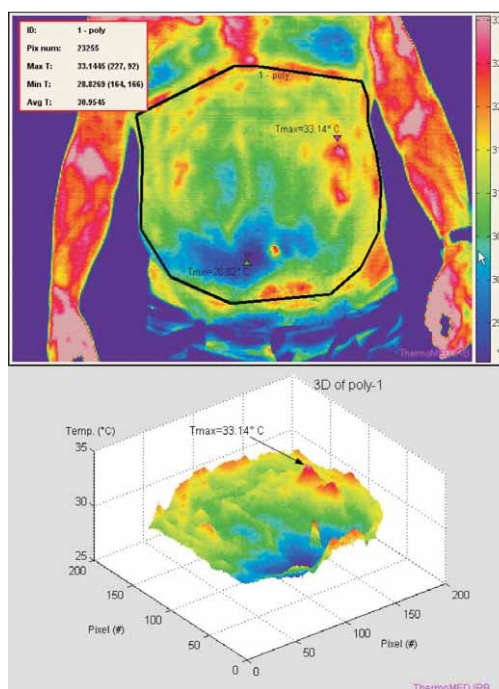


Figure 5 (a and b). A male patient with high-grade dysplastic polypoid lesion in left-sided ulcerative colitis.

clear change is evident in the thermal pattern of the abdominal surface. The main peak temperature after induction of remission was 31.5°C. Still, we noticed a second less expressed peak at 32.5°C.

3. Colonic inflammation and high-grade dysplastic polypoid lesion

Figure 5 shows an example of a hot spot which is above a polypoid lesion with high grade dysplasia. 3D analysis of the that hot spot is on the right.

4. Colorectal cancer

Figure 6 is an anterior and a left lateral thermogram of a female patient with rectosigmoid cancer that shows hot spots probably indicating neoplastic angiogenesis.

5. Possible traps

Figures 7 and 8 show abdominal scarring and pronounced abdominal trichosis as examples of possible traps leading to misinterpretation. Both pronounced trichosis and scarring show increased temperature patterns. Each IR image should be accompanied in this way with the same view photograph.

DISCUSSION AND A VIEWPOINT

Thermography uses thermal imaging which detects new or congested blood vessels and chemical changes associated with inflammation and tumor genesis and growth. Thermal imaging measures the radiation of infrared heat from human body and translates this information into anatomical images. Thus, it offers a very early warning system, often able to pinpoint a cancer process before it would be detectable by standard diag-

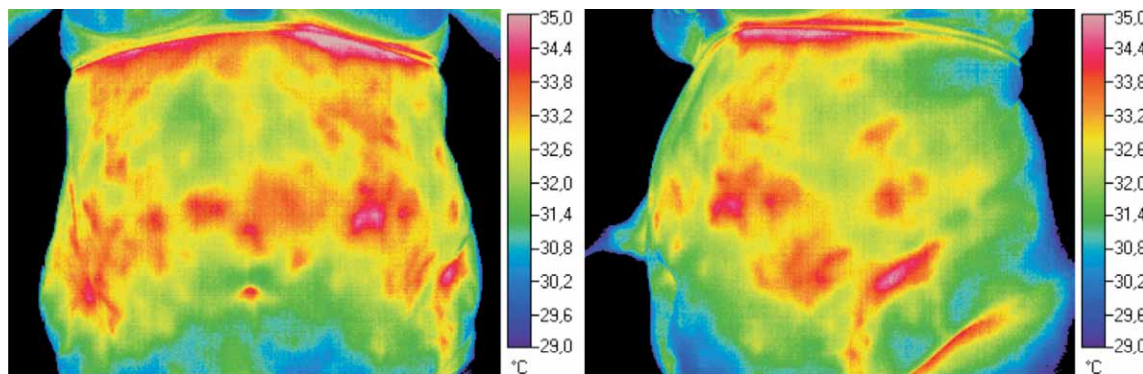


Figure 6 (a and b). Anterior (a) and left lateral (b) thermal image of a female patient with rectosigmoid cancer.

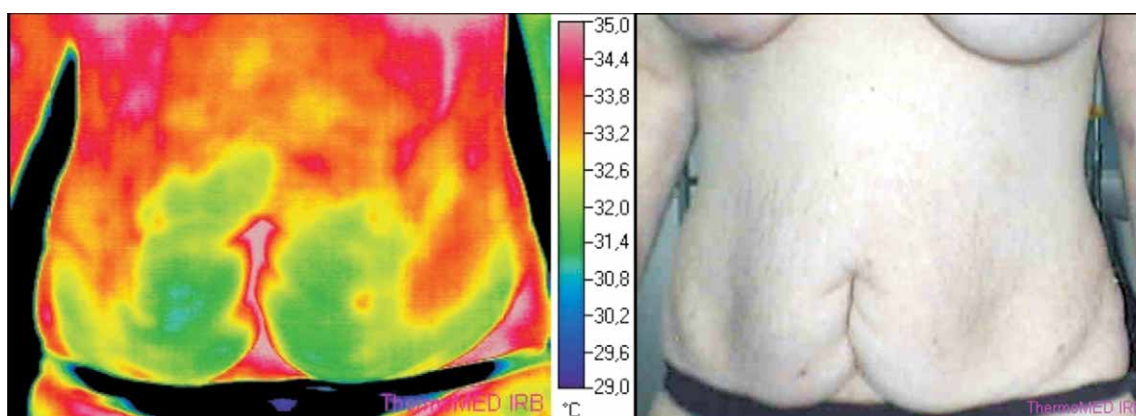


Figure 7 (a and b). The thermal image (a) and the photograph (b) of a female patient with left-sided active colitis and median infraumbilical abdominal scar.

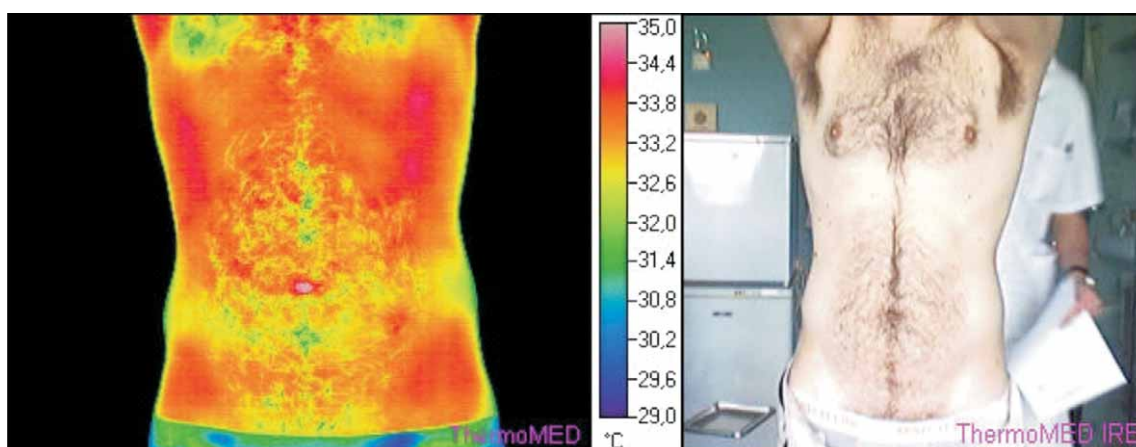


Figure 8 (a and b). The thermal image (a) and the photograph (b) of a male patient with ulcerative pancolitis and pronounced abdominal trichosis.

nostic imaging techniques. On the other hand, a prime candidate at the interface of environment and genetics is chronic inflammation which is known to precede the development of numerous types of precancerous lesions and certain cancers themselves, including oesophageal, liver and colon cancers. Chronic inflammation has been linked with increased DNA methylation in otherwise healthy looking tissue, displaying also the characteristics of an epigenetic phenomenon (16). Ulcerative colitis represents a chronic inflammatory and ulcerative disease of colonic mucosa. Clinically, ulcerative colitis is characterized by bloody diarrhea, and the diagnosis most often relies on colonoscopy and macroscopical scoring of visualized inflammatory and ulcerative mucosal pattern (17-21). Taking into account the standard imaging procedures for evaluating the activity and extent of inflammatory disease, the thermal imaging, also known as clinical thermography, is capable of providing non-contact, *in vivo* diagnostic information in regard to body temperature. Infrared imaging also has the possibility to map small variations in the body surface temperature and identify thermal abnormalities that accompany various physiological conditions. Being a passive technique, (i.e.

without external sources of radiation) thermography is non-invasive and therefore intrinsically harmless.

Limitations regarding method standardization

We believe that blood vessel activity during the process of active inflammation induces an increase in body surface temperature, compared to normal tissue (13). Our findings point to diagnostic potential of infrared thermography as a feasible and noninvasive method in evaluation of disease activity, in patients with severe inflammatory bowel disease, such as acute pancolitis (22-24). There is a need for further basic and clinical studies in order to evaluate and validate the method of thermal imaging that uses infrared thermography to assess the activity and extent of intestinal inflammation and other intraabdominal inflammatory condition.

REFERENCES

1. KATSANOS KH, TSIANOS VE, ZOIS CD, ZIOGA H, VAGIAS I, ZERVOU E, CHRISTODOLOU DK, TSIANOS EV 2010 Inflammatory bowel disease and hepatitis B and C in Western Balkans: a referral centre study and review of the literature. *J Crohns Colitis* 4: 450-465

2. SILVA L C, ORTIGOSA L C, BENARD G 2010 Anti-TNF- α agents in the treatment of immune-mediated inflammatory diseases: mechanisms of action and pitfalls. *Immunotherapy* 2: 817–833
3. FIORINO G, PEYRIN-BIROULET L, REPICI A, MALESCI A, DANESE S 2011 Adalimumab in ulcerative colitis: hopes and hopes. *Expert Opin Biol Ther* 11: 109–116
4. DE NITTO D, SARRA M, CUPI M L, PALLONE F, MONTELEONE G 2010 Targeting IL-23 and Th17-cytokines in inflammatory bowel diseases. *Curr Pharm Des* 16: 3656–3660
5. PLEŠKO S, BANIĆ M, PLEČKO V, ANIĆ B, BRKIĆ T, RENATA H, ROTKVIĆ I 2010 Effect of azithromycin on acute inflammatory lesions and colonic bacterial load in a murine model of experimental colitis. *Dig Dis Sci* 55: 2211–2218
6. BANIĆ M, ANIĆ B, BRKIĆ T *et al* 2002 Effect of cyclosporine in a murine model of experimental colitis. *Dig Dis Sci* 47: 1362–1368
7. KAMINSKI MF, REGULA J, KRASZEVSKA E, POLKOWSKI M, WOJCIECHOWSKA U, DIDKOWSKA J, ZWIERKO M, RUPINSKI M, NOWACKI MP, BUTRUK E 2010 Quality indicators for colonoscopy and the risk of interval cancer. *N Engl J Med* 362: 1795–1803
8. JONES B F, PLASSMANN P 2002 Digital infrared thermal imaging of human skin. *IEEE Eng. Med Biol* 21: 41–48
9. DIAKIDES N A, DIAKIDES M, LUPO J C, PAUL J L, BALCERAK R 2008 Advances in Medical Infrared Imaging. In: Diakides N A, Bronzino J D (eds) Medical infrared imaging. Boca Raton: CRC Press Taylor and Francis Group, p 1-1, 1–13
10. GRENN M W, VIZGAITIS J, PELLEGRINO J G, PERCONTI P 2008 Infrared camera and optics for medical applications. In: Diakides N A, Bronzino J D (eds) Medical infrared imaging. Boca Raton: CRC Press Taylor and Francis Group, p 5-1, 5–14
11. KOLARIĆ D, SKALA K, DUBRAVIĆ A 2007 ThermoWEB-remote control and measurement of temperature over Web. *Period Biol* 108: 631–637
12. KOLARIĆ D, LIPIĆ T, GRUBIŠIĆ I, GJENERO L, SKALA K 2011 Application of Infrared Thermal Imaging in Blade System Temperature Monitoring. In: Božek J, Grgić M (eds) Proceedings of the fifty third International Symposium ELMAR. Croatian Society Electronics in Marine – ELMAR, Zadar, p 309–312
13. BANIĆ M, KOLARIĆ D, ANTONINI S, FERENČIĆ Ž, PLEŠKO S, PETRIČUŠIĆ L 2011 Potential role of thermography in evaluation of disease activity in inflammatory bowel disease – a case report. In: Božek J, Grgić M (eds) Proceedings of the fifty third International Symposium ELMAR. Croatian Society Electronics in Marine – ELMAR, Zadar, p 289–291
14. MERLA A, ROMANI G L 2008 Biomedical applications of functional infrared imaging. In: Diakides N A, Bronzino J D (eds) Medical infrared imaging. Boca Raton: CRC Press Taylor and Francis Group, p 15-1, 15–20
15. VOLLMER M, MOELLMAN K P 2010 Infrared Thermal Imaging: Fundamental, Research and Applications. Wiley – VCH, Berlin.
16. FAITHFULL N S, REINHOLD P R, VAN DER BERG A P, VAN DER ZEE J, WIKE-HOOLEY J L 1984 Cardiovascular challenges during whole body hyperthermia treatment of advanced malignancy. *Eur J Appl Physiol* 53: 274–281
17. BROWER W 2011 Epigenetics: Unravelling the cancer code. *Nature* 471: S12–S13
18. PREISS J C, ZEITZ M 2010 Use of methotrexate in patients with inflammatory bowel diseases. *Clin Exp Rheumatol* 28: S151–S155
19. TALLEY N J, ABREU M T, ACHKAR J P, BERNSTEIN C N, DUBINSKY M C, HANAUER S B, KANE S V, SANDBORN W J, ULLMAN T A, MOAYYEDI P 2011 An evidence-based systematic review on medical therapies for inflammatory bowel disease. *Am J Gastroenterol* 106 Suppl 1 6: S2–S25.
20. VALENTINI L, SCHULZKE J D 2011 Mundane, yet challenging: the assessment of malnutrition in inflammatory bowel disease. *Eur J Intern Med* 22: 13–15
21. DINESEN L C, WALSH A J, PROTIC M N, HEAP G, CUMMINGS F, WARREN B F, GEORGE B, MORTENSEN N J, TRAVIS S P 2010 The pattern and outcome of acute severe colitis. *J Crohns Colitis* 4: 431–437
22. BRAKENHOFF L K, VAN DER HEIJDE D M, HOMMES D W, HUIZINGA T W, FIDDER H H 2010 The joint-gut axis in inflammatory bowel diseases. *J Crohns Colitis* 4: 257–268
23. PUROHIT R C, TURNER T A, PASCOE D D 2008 Use of infrared imaging in Veterinary Medicine. In: Diakides N A, Bronzino J D (eds) Medical infrared imaging. Boca Raton: CRC Press Taylor and Francis Group, p 21-1, 21–8
24. GIORDANO J 2008 Ethical obligations in infrared imaging research and practice. In: Diakides N A, Bronzino J D (eds) Medical infrared imaging. Boca Raton: CRC Press Taylor and Francis Group, p 21-1, 21–8